

# Chapter 1 An Introduction to Anatomy

---

## Multiple Choice

- 1) Which is the most accurate statement?
- A) Historically, the relationship between superficial anatomy and internal function has always been understood.
  - B) Many cellular functions were known decades before the electron microscope revealed the anatomical basis for those functions.
  - C) Anatomy has always been known to reveal the relationship between body parts.
  - D) Ancient anatomists only described surface anatomy.
  - E) Ancient anatomists never understood the function of anatomical features.

Answer: B

- 2) The branch of science that studies groups of cells and how they work together is called
- A) physiology.
  - B) histology.
  - C) anatomy.
  - D) serology.
  - E) none of the above.

Answer: B

- 3) It is important to study the discipline of anatomy because
- A) it is important to understand the link between human structure and function.
  - B) it provides information about both external and internal structures.
  - C) it will assist individuals to make informed decisions about their personal health.
  - D) it provides a basis for understanding more advanced courses in anatomy, physiology, and related disciplines.
  - E) all of the above apply.

Answer: E

- 4) Which of the following statements about anatomical information is correct?
- A) Anatomic information is all historical.
  - B) It describes body parts and considers probable function.
  - C) It addresses large body structures visible to the naked eye only.
  - D) Physiology and anatomy are unrelated.
  - E) The study of cells is useless to anatomy.

Answer: B

- 5) Analysis of the internal structure of an individual cell is
- A) cytology.
  - B) physiology.
  - C) histology.
  - D) embryology.
  - E) osteology.

Answer: A

6) The study of structures by viewing them with special instrumentation is called

- A) cytology.
- B) embryology.
- C) physiology.
- D) histology.
- E) radiography.

Answer: E

7) The anatomical specialty that examines changes in form from conception to maturity is

- A) developmental anatomy.
- B) comparative anatomy.
- C) medical anatomy.
- D) surgical anatomy.
- E) systemic anatomy.

Answer: A

8) The study of anatomy includes which of the following?

- A) organs.
- B) communities.
- C) ecosystems.
- D) colonies.
- E) populations.

Answer: A

9) At which level of organization do multiple tissues form larger structures that perform specific functions?

- A) cellular
- B) organ
- C) organ system
- D) tissue
- E) organism

Answer: B

10) The largest level of organization listed is

- A) molecules.
- B) organelles.
- C) cells.
- D) tissues.
- E) organs.

Answer: E

11) The molecular events that result in muscle contraction most directly involve which level of organization of body structures?

- A) chemical
- B) tissue
- C) organ
- D) cellular
- E) organism

Answer: A

- 12) The major function of the \_\_\_\_\_ system is protection of the body from the external environment.
- A) digestive
  - B) cardiovascular
  - C) urinary
  - D) respiratory
  - E) integumentary

Answer: E

- 13) The basic functions performed by all living organisms include(s)
- A) reproduction.
  - B) metabolism.
  - C) growth.
  - D) movement.
  - E) all of the above are performed by all living organisms.

Answer: E

- 14) Which of the following includes *only* structures enclosed within the mediastinum?
- A) lungs, esophagus, heart
  - B) heart, trachea, lungs
  - C) esophagus, trachea, thymus
  - D) pharynx, thymus, major vessels
  - E) brain, spinal cord

Answer: C

- 15) Organs of the urinary system include
- A) ureters and kidneys.
  - B) liver and pancreas.
  - C) thymus and spleen.
  - D) bronchi and alveoli.
  - E) none of the above.

Answer: A

- 16) The serous membrane that lines the inside surface of the thoracic cavity is the
- A) visceral peritoneum.
  - B) parietal pericardium.
  - C) parietal pleura.
  - D) visceral pericardium.
  - E) none of the above.

Answer: C

- 17) The \_\_\_\_\_ lines the body wall within the abdominopelvic cavity.
- A) visceral pleura
  - B) parietal pericardium
  - C) mesentery proper
  - D) superficial fascia
  - E) parietal peritoneum

Answer: E

18) Mesenteries

- A) provide a passageway for blood vessels to the abdominal organs.
- B) allow movement of abdominal structures.
- C) support and stabilize organs such as the kidneys.
- D) do all of the above.
- E) do none of the above.

Answer: A

19) Most anatomical terms have been derived from

- A) Romance languages.
- B) German.
- C) Latin and Greek.
- D) English.
- E) Arabic.

Answer: C

20) In the prone position,

- A) the body faces posteriorly.
- B) the body is lying in anatomical position face up.
- C) the body is lying in anatomical position face down.
- D) the head is turned to the left, and the eyes are closed.
- E) the body is situated as in both A and B.

Answer: C

21) In anatomical description, a person is said to be supine when

- A) standing upright in the anatomical position.
- B) standing with hands rotated out of the anatomical position.
- C) lying face down in the anatomical position.
- D) lying face up in the anatomical position.
- E) lying on his or her side in a fetal position.

Answer: D

22) A coronal section is in a plane that

- A) is at right angles to the longitudinal axis.
- B) divides the body into left and right sections.
- C) divides the body into anterior and posterior sections.
- D) divides the body into superior and inferior sections.
- E) divides the body into frontal sections.

Answer: C

23) The thoracic cavity is separated from the abdominopelvic cavity by

- A) the inferior border of the rib cage.
- B) a sheet of connective tissue.
- C) the diaphragm.
- D) the liver.
- E) none of the above.

Answer: C

24) The linings of both the oral and nasal cavities are

- A) mucous membranes.
- B) serous membranes.
- C) lymphoid tissues.
- D) contractile tissues.
- E) sheets of tendon.

Answer: A

25) What is the function of the parietal parts of the membranes lining the ventral body cavity?

- A) They secrete lubrication to allow organs to slide by one another without friction.
- B) They supply nutrients to the viscera within the various subdivisions of the cavity.
- C) They suspend organs from the mediastinum.
- D) They maintain organ separation.
- E) They do none of the above.

Answer: A

26) The space found between the lungs and superior to the heart is called the

- A) mediastinum.
- B) pleural cavity.
- C) pericardial cavity.
- D) ventral cavity.
- E) thoracic cavity.

Answer: A

27) The pericardial cavity contains which of the following?

- A) heart
- B) liver
- C) intestines
- D) brain
- E) both A and B

Answer: A

28) The viscera (or guts) occupy a space known as the \_\_\_\_\_ body cavity.

- A) cranial
- B) orbital
- C) dorsal
- D) ventral
- E) vertebral

Answer: D

29) Which of the following organs occupies the pelvic cavity?

- A) brain
- B) urinary bladder
- C) spinal cord
- D) esophagus
- E) pancreas

Answer: B

30) Which of the following is considered a radiological procedure?

- A) CT (computerized tomography)
- B) MRI (magnetic resonance imaging)
- C) ultrasound
- D) angiography
- E) all of the above

Answer: E

31) Gross anatomical specialties include

- A) radiographic and surgical anatomy.
- B) cytology and embryology.
- C) histology.
- D) both A and B.
- E) both B and C.

Answer: A

32) Choose the arrangement of items 1–5 in order of decreasing complexity of level of organization.

- (1) organism
  - (2) tissue
  - (3) chemical or molecular
  - (4) cellular
  - (5) organ system
- A) 1, 2, 3, 4, 5
  - B) 5, 4, 3, 2, 1
  - C) 1, 5, 2, 4, 3
  - D) 5, 3, 2, 4, 1
  - E) 2, 4, 1, 5, 3

Answer: C

33) Which of the following are basic functions performed by all living organisms?

- A) responsiveness and growth
- B) movement, reproduction, and absorption
- C) metabolism and excretion
- D) all of the above
- E) A and C only

Answer: D

34) Excretion involves

- A) changes to adjust to an organism's environment.
- B) creation of a new generation of individuals.
- C) transport of substances within an organism.
- D) elimination of waste materials from the body.
- E) both B and C.

Answer: D

35) Growth and differentiation often include

- A) specialization of individual cells.
- B) increase in cell size.
- C) increase in cell numbers.
- D) changes in form and function.
- E) all of the above.

Answer: E

36) Support, protection, mineral storage, and blood cell formation are functions of the

- A) skeletal system.
- B) cardiovascular system.
- C) immune system.
- D) reproductive system.
- E) excretory system.

Answer: A

37) How are the structure and function of a body organ or system related?

- A) There is no relationship.
- B) Organ structure only occasionally relates to function.
- C) Structure and function relate only generally.
- D) All specific functions are performed by specific structures or organs.
- E) At some times, structure relates to function; at other times it does not.

Answer: D

38) The two layers of a serous membrane are

- A) pericardial and parietal.
- B) double sheets of peritoneum.
- C) visceral and parietal.
- D) pleural and parietal.
- E) A and B only.

Answer: C

39) The primary site of blood cell production is within the

- A) cardiovascular system.
- B) skeletal system.
- C) integumentary system.
- D) lymphoid system.
- E) endocrine system.

Answer: B

40) Organs systems are

- A) anatomical units with related functions.
- B) formed by two or more organs.
- C) often large enough to be studied without magnification.
- D) interdependent on each other.
- E) all of the above.

Answer: E

41) Which of the following pairs consists of anatomical opposites?

- A) distal, coronal
- B) proximal, lateral
- C) cranial, caudal
- D) cephalic, posterior
- E) medial, ventral

Answer: C

42) Why does the term *caudal* differ in meaning in humans versus four-legged animals (quadrupeds)?

- A) All human anatomical terms are different from those used for quadrupeds.
- B) Humans' upright stance makes caudal the same as inferior.
- C) Caudal is a relative term, meaning posterior in humans.
- D) It doesn't; the meaning is the same in both.
- E) None of the above explains the difference.

Answer: B

43) A transverse section at the level of the umbilicus would pass through which body cavity?

- A) dorsal cavity
- B) thoracic cavity
- C) abdominal cavity
- D) pelvic cavity
- E) none of the above

Answer: C

### Fill-in-the-Blank and Matching

1) The literal translation of the word \_\_\_\_\_, which is derived from the Greek, describes this branch of science and means "to cut open."

Answer: anatomy

2) The study of anatomy leads to an important concept that structure determines \_\_\_\_\_.

Answer: function

3) Study of general form and superficial anatomical markings is called \_\_\_\_\_ anatomy.

Answer: surface

4) \_\_\_\_\_ anatomy is the consideration of anatomical structures large enough to be viewed by the naked eye.

Answer: Gross

5) Study of the changes in form that occur during the period from conception to physical maturity is called \_\_\_\_\_ anatomy.

Answer: developmental

6) \_\_\_\_\_ is the study of the smallest living units.

Answer: Cytology

7) More than one \_\_\_\_\_ combines to increase complexity and promote the level of organization to the organ level.

Answer: tissue



8) \_\_\_\_\_ is the process of producing a new organism.

Answer: Reproduction

9) \_\_\_\_\_ is a basic function of a living organism that governs how the individual reacts to stimuli.

Answer: Responsiveness

10) The process of cellular specialization to perform certain functions is called \_\_\_\_\_.

Answer: differentiation

11) \_\_\_\_\_ is the property of living organisms whereby they discharge useless or harmful wastes produced during normal function.

Answer: Excretion

12) The property of living things to change position is called \_\_\_\_\_.

Answer: movement

13) The \_\_\_\_\_ system contains glandular structures that direct long-term changes in the activities of other organ systems.

Answer: endocrine

14) The \_\_\_\_\_ system breaks chemicals down and absorbs them into the body.

Answer: digestive

15) A \_\_\_\_\_ plane is a horizontal or cross-sectional plane intersecting the human body at right angles to the long axis.

Answer: transverse

16) A midsagittal section divides the human body into equal \_\_\_\_\_ and \_\_\_\_\_ portions.

Answer: left; right

17) Most of the digestive organs are contained within the \_\_\_\_\_ cavity, which is named for the membrane that surrounds it.

Answer: peritoneal

18) The hip is \_\_\_\_\_ to the knee.

Answer: proximal

19) The nipple is \_\_\_\_\_ and \_\_\_\_\_ to the umbilicus.

Answer: superior; lateral

20) The anatomical name for the front of the elbow is \_\_\_\_\_.

Answer: antecubitus

21) The hips are \_\_\_\_\_, or inferior, to the shoulders.

Answer: caudal

22) An imbalance in the function of the body is known as \_\_\_\_\_.

Answer: disease

23) The outer surfaces of each lung are covered by the \_\_\_\_\_ pleura.

Answer: visceral

24) The bladder is located in the \_\_\_\_\_ cavity.

Answer: pelvic

25) The \_\_\_\_\_ separates the thoracic from the abdominal cavity.

Answer: diaphragm

26) Heart is to pericardial cavity as \_\_\_\_\_ is to pleural cavity.

Answer: lung

27) Organs such as the liver, stomach, and pancreas are located within the \_\_\_\_\_ cavity, superior to the level of the pelvis.

Answer: abdominal

28) The \_\_\_\_\_ layer of the serous membrane is attached to the surfaces of organs in the ventral body cavity.

Answer: visceral

29) The pericardium lies within the \_\_\_\_\_, a portion of the thoracic cavity that lies between the left and right pleural cavities.

Answer: mediastinum

30) The branch of anatomy that studies structures too small to be seen with the naked eye is called \_\_\_\_\_ anatomy.

Answer: microscopic

31) \_\_\_\_\_ is the discipline that might examine structural interactions within a sheet of muscle tissue.

Answer: Histology

32) A \_\_\_\_\_ section is produced if the body is separated into top and bottom portions.

Answer: transverse

33) Damage to body structures at any level would most impair function at the highest, or \_\_\_\_\_, level of organization.

Answer: organism

34) The \_\_\_\_\_ system allows for gas exchange with the environment.

Answer: respiratory

35) The respiratory system makes it possible for the body to conduct gas exchange; this process is also facilitated by the \_\_\_\_\_ system.

Answer: cardiovascular

36) The calf is more appropriately called the \_\_\_\_\_.

Answer: sura

37) The thoracic and abdominopelvic cavities constitute the \_\_\_\_\_ body cavity.

Answer: ventral

38) Pain originating from the spleen would most likely be felt in the \_\_\_\_\_ abdominopelvic quadrant.

Answer: left upper

- 39) The \_\_\_\_\_ abdominopelvic region is sandwiched between the right and left hypochondriac regions.

Answer: epigastric

*Match each anatomical directional term with its opposite.*

- (a) *medial*
- (b) *inferior*
- (c) *caudal*
- (d) *anterior*
- (e) *distal*

- 40) cranial

Answer: c

- 41) proximal

Answer: e

- 42) lateral

Answer: a

- 43) superior

Answer: b

- 44) posterior

Answer: d

*Match each anatomical term with the area of the body indicated.*

- (a) *tarsus*
- (b) *manus*
- (c) *bucca*
- (d) *gluteus*
- (e) *cervicis*

- 45) buttock

Answer: d

- 46) ankle

Answer: a

- 47) foot

Answer: c

- 48) cheek

Answer: c

- 49) hand

Answer: b

*Match each anatomical approach or specialty with its emphasis.*

- (a) *radiographic anatomy*
- (b) *developmental anatomy*
- (c) *systemic anatomy*
- (d) *microscopic anatomy*
- (e) *regional anatomy*

50) Uses magnification

Answer: d

51) Changes over time

Answer: b

52) Study of all things in an area

Answer: e

53) Study of one group at a time

Answer: c

54) Uses radioisotopes, magnets, and X-rays

Answer: a

*Match each level of organization with its description below.*

- (a) *organism level*
- (b) *cellular level*
- (c) *organ level*
- (d) *chemical level*
- (e) *tissue level*

55) Cellular structures and functions focus attention at the \_\_\_\_\_.

Answer: b

56) Atoms interacting to form components with distinctive properties in the body show organization at the \_\_\_\_\_.

Answer: d

57) Multiple tissues that interact to perform a united group of functions show organization at the \_\_\_\_\_.

Answer: c

58) Specialized cell types united to perform a distinctive group of shared functions show organization at the \_\_\_\_\_.

Answer: e

59) Interactions among organ systems demonstrate function at the \_\_\_\_\_.

Answer: a

*Match each word with its most specific description below.*

- (a) *disease*
- (b) *sign*
- (c) *symptom*
- (d) *diagnosis*
- (e) *pathology*

60) An unusual functioning of the body as described by a patient.

Answer: c

61) The study of illness.

Answer: e

62) Illness, or imbalance.

Answer: a

63) A specific designation of a condition of functioning.

Answer: d

64) A visible clue on a patient.

Answer: b

## Essay

1) How does microscopy differ from viewing structures with the naked eye?

Answer: Microscopy involves the study of structures too small to be seen by the naked eye. When structures are viewed with the unaided eye, the entire three-dimensional structure can be seen as well as its relationship to other structures. Structures observed by microscopy are seen only in a two-dimensional plane; some sections may be difficult to interpret.

2) How are the levels of organization of body structures related to each other?

Answer: Each complex level is totally dependent upon all the levels that are less complex, because damage at the level of the smallest structure affects larger and more complex structures throughout the system.

3) In general, why must larger organisms have specialized structures to permit some life functions to occur?

Answer: In large organisms, specialized structures are required for movement of materials through exposed surfaces and transport of materials between body regions because (1) many cells are too far from an exposed surface and (2) there is not enough total surface area to allow all of the body's cells to exchange nutrients, oxygen, and wastes directly with the environment. Other life functions, such as reproduction, are also complicated by organisms' larger size.

4) What is the role of serous membranes in the body?

Answer: Serous membranes provide a slippery cover for the inside of the ventral body cavities and the outside of most organs located in these cavities. This slippery lining prevents friction between moving organs and the body wall.

5) Why is it important to be familiar with major anatomical landmarks?

Answer: Major landmarks have a consistent location with respect to other structures, and can give an idea of the location of structures that cannot be seen because they are internal to the skin.

6) How does the definition of *posterior*, as it is used in human terminology, differ from the usage with four-legged animals (quadrupeds)?

Answer: Posterior means "behind," which is equivalent to dorsal ("the back") in humans. Because of the difference in standing position, the two terms are not equivalent in quadrupeds, dorsal still meaning the back of the animal, but posterior meaning the tail (or caudal) end.

7) How does comparative anatomy contribute to the study of human gross anatomy?

Answer: Observed similarities of anatomical structure among different species of animals demonstrate evolutionary relationships and the similarity of developmental processes. Comparison of the same systems among different animals also shows how these systems are adapted to serve different anatomical and physiological functions.

8) How does the regional approach differ from the systemic approach in the study of anatomy?

Answer: Systemic anatomy considers all of the components of each organ system simultaneously. Regional anatomy considers all of the superficial and internal structures in a specific area of the body, regardless of the organ system.

9) What is the function of an organ system in the body?

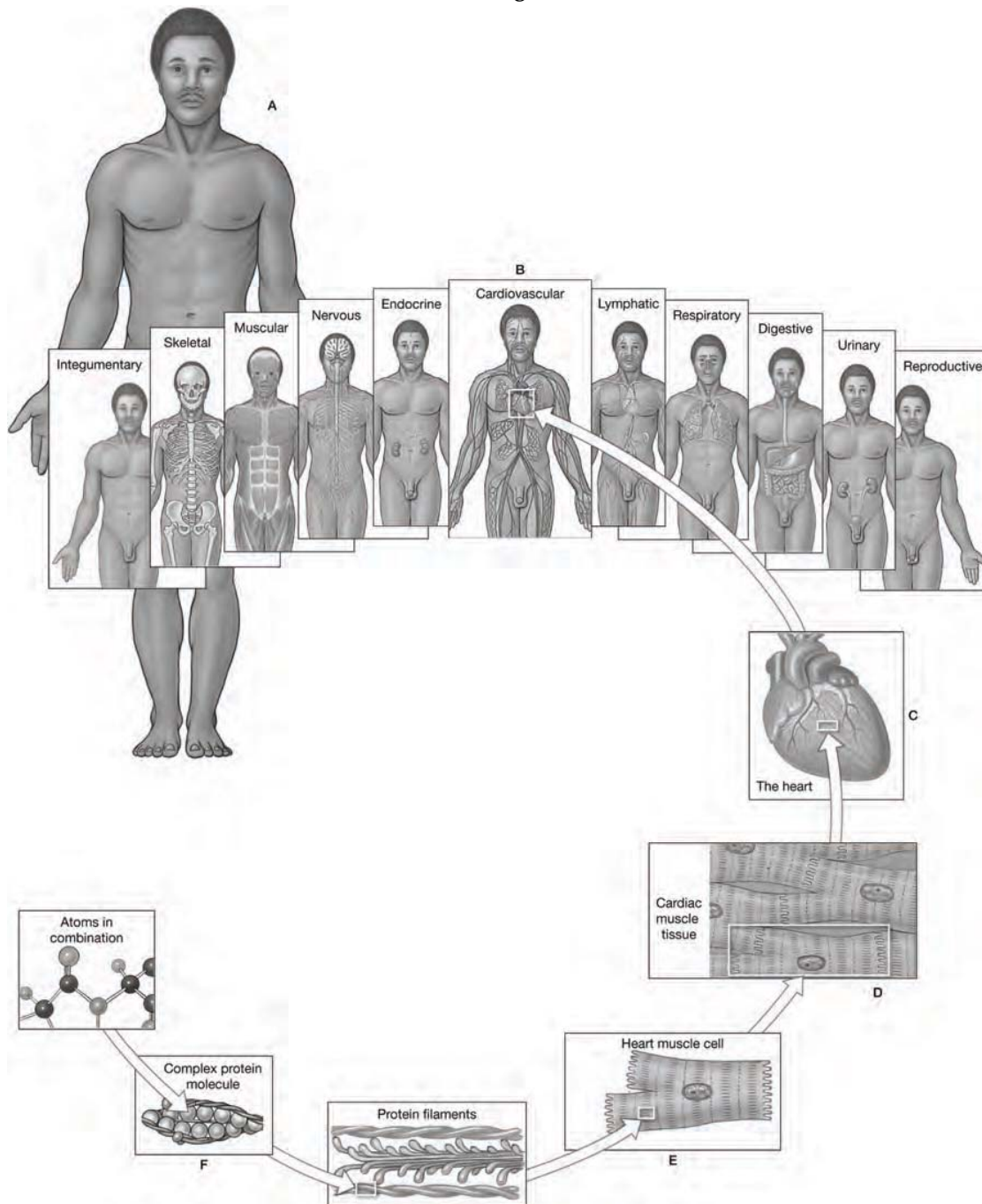
Answer: Organ systems are groups of organs that function together to produce coordinated effects.

10) What is the basic anatomical pattern that humans and other vertebrate animals share?

Answer: All of these organisms show bilateral symmetry, two sets of paired limbs, and a cephalic location for most of the organs of the special senses. All vertebrates have a hollow dorsal nerve cord, dorsal and ventral body cavities, and a postanal tail, although in humans this structure is reduced to the four elements of the coccyx. All vertebrates also share the "tube within a tube" pattern of hollow body cavities that contain tubular structures, such as the digestive tract. At some stage of development (often only embryonic), vertebrates also have a notochord and pharyngeal (gill) arches.

## Labeling Exercises

Figure 1.1



Identify the levels of organization in the figure above.

1) Label A: \_\_\_\_\_

Answer: Organismal level

2) Label B: \_\_\_\_\_

Answer: Organ system level

3) Label C: \_\_\_\_\_

Answer: Organ level

4) Label D: \_\_\_\_\_

Answer: Tissue level

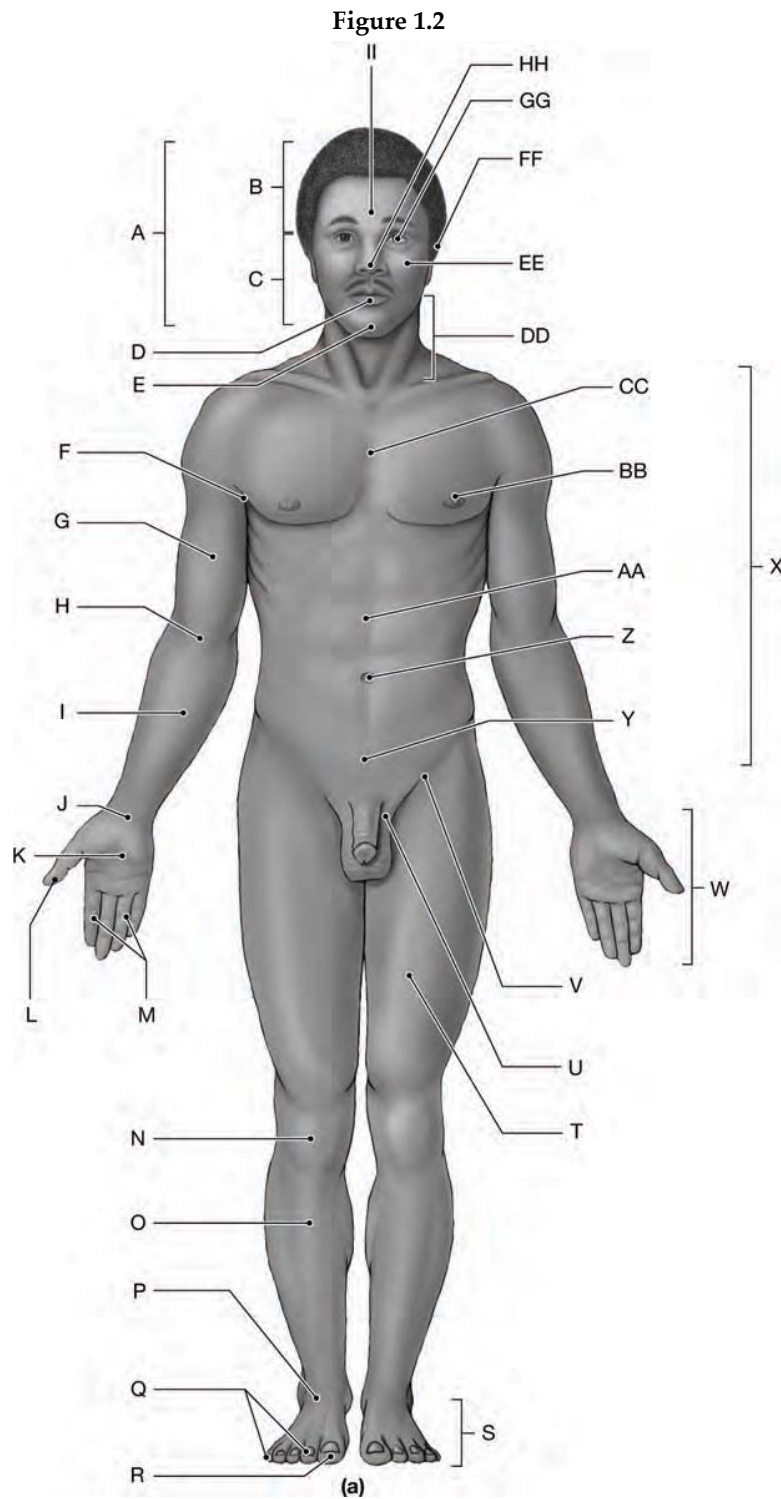
5) Label E: \_\_\_\_\_

Answer: Cellular level

6) Label F: \_\_\_\_\_

Answer: Chemical or molecular level





Using the figure above, identify the labeled part.

7) Label A: \_\_\_\_\_

Answer: Cephalon or head (cephalic)

8) Label B: \_\_\_\_\_

Answer: Cranium or skull (cranial)

9) Label C: \_\_\_\_\_

Answer: Facies or face (facial)

10) Label D: \_\_\_\_\_

Answer: Oris or mouth (oral)

11) Label E: \_\_\_\_\_

Answer: Mentis or chin (mental)

12) Label F: \_\_\_\_\_

Answer: Axilla or armpit (axillary)

13) Label G: \_\_\_\_\_

Answer: Brachium or arm (brachial)

14) Label H: \_\_\_\_\_

Answer: Antecubitus or front of elbow (antecubital)

15) Label I: \_\_\_\_\_

Answer: Antebrachium or forearm (antebrachial)

16) Label J: \_\_\_\_\_

Answer: Carpus or wrist (carpal)

17) Label K: \_\_\_\_\_

Answer: Palma or palm (palmar)

18) Label L: \_\_\_\_\_

Answer: Pollex or thumb

19) Label M: \_\_\_\_\_

Answer: Digits (phalanges) or fingers (digital or phalangeal)

20) Label N: \_\_\_\_\_

Answer: Patella or kneecap (patellar)

21) Label O: \_\_\_\_\_

Answer: Crus or leg (crural)

22) Label P: \_\_\_\_\_

Answer: Tarsus or ankle (tarsal)

23) Label Q: \_\_\_\_\_

Answer: Digits (phalanges) or toes (digital or phalangeal)

24) Label R: \_\_\_\_\_

Answer: Hallux or great toe

25) Label S: \_\_\_\_\_

Answer: Pes or foot (pedal)

26) Label T: \_\_\_\_\_

Answer: Femur or thigh (femoral)

27) Label U: \_\_\_\_\_

Answer: Pubis (pubic)

28) Label V: \_\_\_\_\_

Answer: Inguen or groin (inguinal)

29) Label W: \_\_\_\_\_

Answer: Manus or hand (manual)

30) Label X: \_\_\_\_\_

Answer: Trunk

31) Label Y: \_\_\_\_\_

Answer: Pelvis (pelvic)

32) Label Z: \_\_\_\_\_

Answer: Umbilicus or navel (umbilical)

33) Label AA: \_\_\_\_\_

Answer: Abdomen (abdominal)

34) Label BB: \_\_\_\_\_

Answer: Mamma or breast (mammary)

35) Label CC: \_\_\_\_\_

Answer: Thoracis or thorax, chest (thoracic)

36) Label DD: \_\_\_\_\_

Answer: Cervicis or neck (cervical)

37) Label EE: \_\_\_\_\_

Answer: Bucca or cheek (buccal)

38) Label FF: \_\_\_\_\_

Answer: Auris or ear (otic)

39) Label GG: \_\_\_\_\_

Answer: Oculus or eye (orbital or ocular)

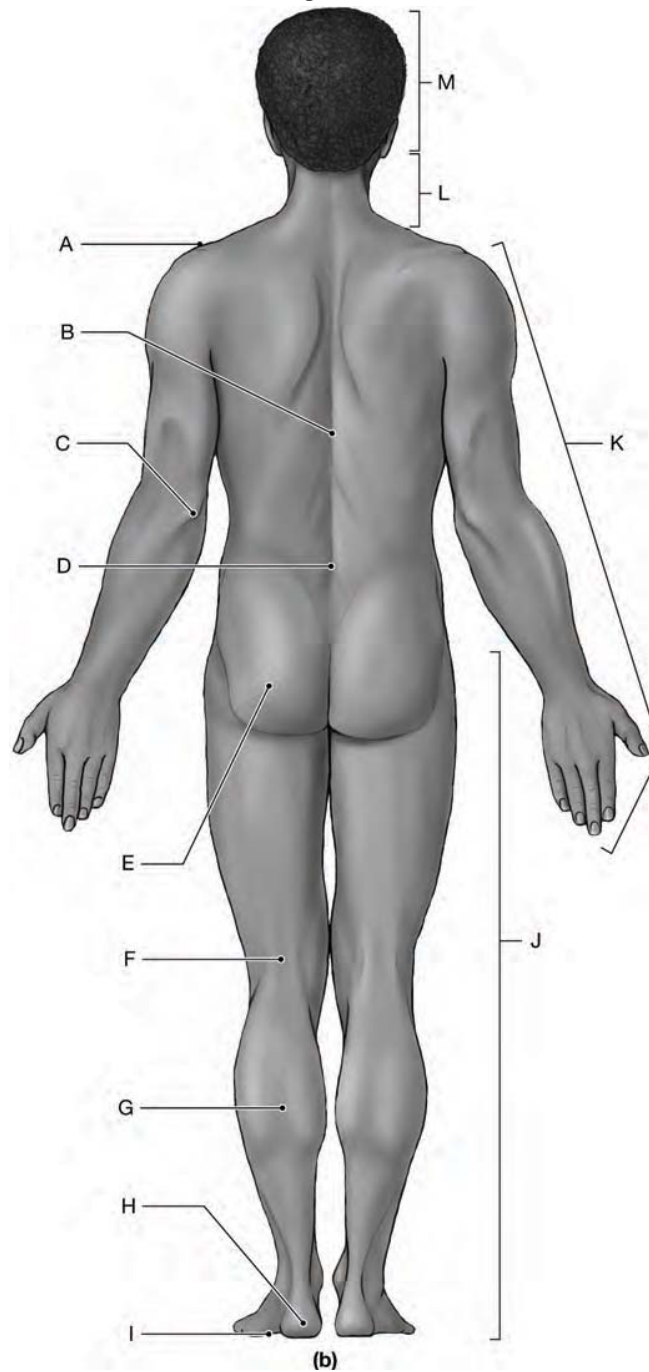
40) Label HH: \_\_\_\_\_

Answer: Nasus or nose (nasal)

41) Label II: \_\_\_\_\_

Answer: Frons or forehead (frontal)

Figure 1.3



Using the figure above, identify the labeled part.

42) Label A: \_\_\_\_\_

Answer: Shoulder (acromial)

43) Label B: \_\_\_\_\_

Answer: Dorsum or back (dorsal)

44) Label C: \_\_\_\_\_

Answer: Olecranon or back of elbow (olecranal)

45) Label D: \_\_\_\_\_

Answer: Lumbus or loin (lumbar)

46) Label E: \_\_\_\_\_

Answer: Gluteus or buttock (gluteal)

47) Label F: \_\_\_\_\_

Answer: Popliteus or back of knee (popliteal)

48) Label G: \_\_\_\_\_

Answer: Sura or calf (sural)

49) Label H: \_\_\_\_\_

Answer: Calcaneus or heel of foot (calcaneal)

50) Label I: \_\_\_\_\_

Answer: Planta or sole of foot (plantar)

51) Label J: \_\_\_\_\_

Answer: Lower limb

52) Label K: \_\_\_\_\_

Answer: Upper limb

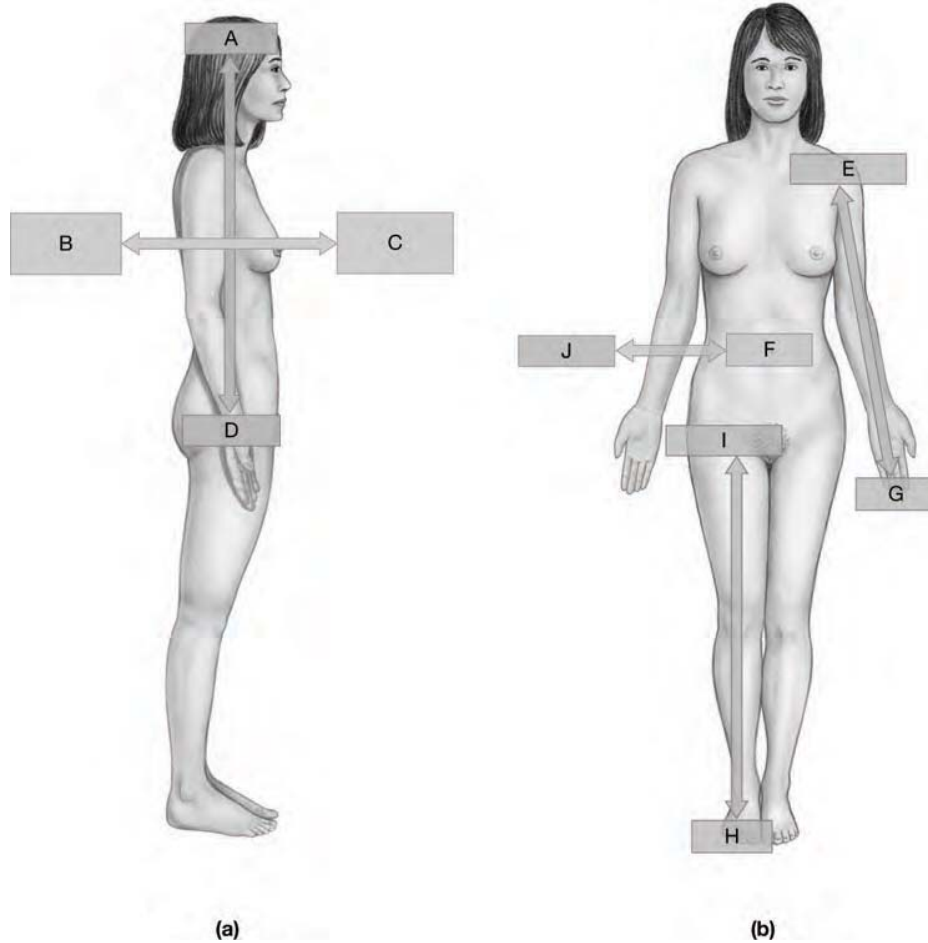
53) Label L: \_\_\_\_\_

Answer: Cervicis or neck (cervical)

54) Label M: \_\_\_\_\_

Answer: Cephalon or head (cephalic)

Figure 1.4



Using the figure above, identify the labeled part.

55) Label A: \_\_\_\_\_

Answer: Cranial

56) Label B: \_\_\_\_\_

Answer: Posterior or dorsal

57) Label C: \_\_\_\_\_

Answer: Anterior or ventral

58) Label D: \_\_\_\_\_

Answer: Caudal

59) Label E: \_\_\_\_\_

Answer: Proximal

60) Label F: \_\_\_\_\_

Answer: Medial

61) Label G: \_\_\_\_\_

Answer: Distal

62) Label H: \_\_\_\_\_

Answer: Distal

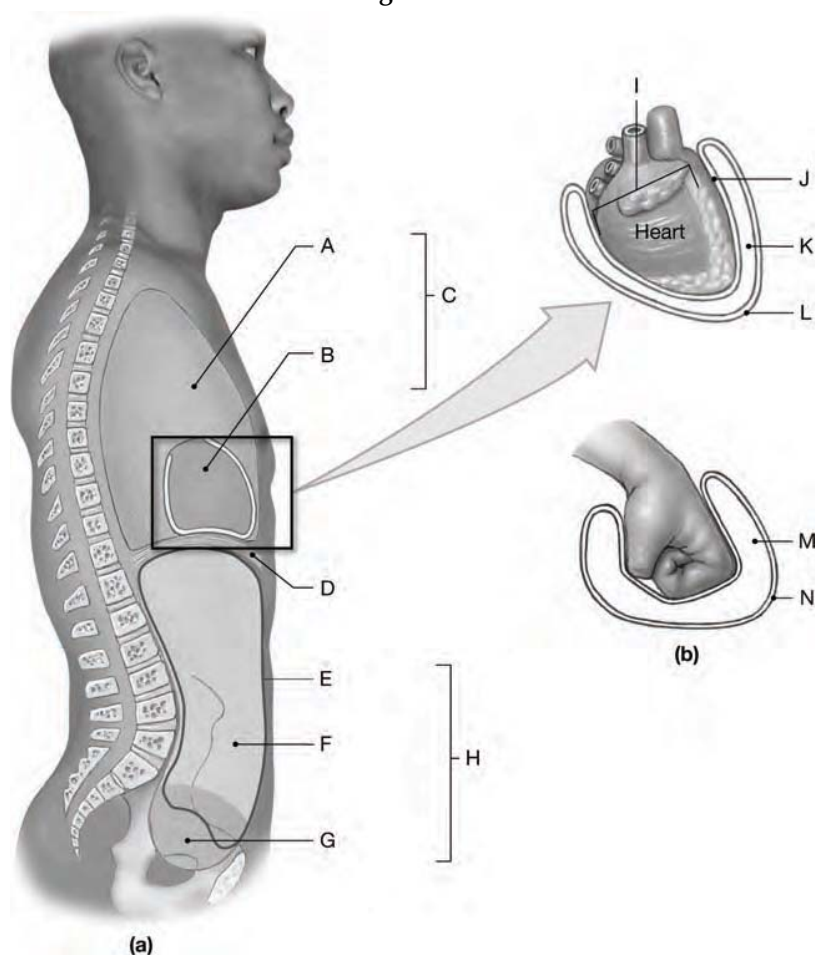
63) Label I: \_\_\_\_\_

Answer: Proximal

64) Label J: \_\_\_\_\_

Answer: Lateral

**Figure 1.5**



Using the figure above, identify the labeled part.

65) Label A: \_\_\_\_\_

Answer: Pleural cavity

66) Label B: \_\_\_\_\_

Answer: Pericardial cavity

67) Label C: \_\_\_\_\_

Answer: Thoracic cavity

68) Label D: \_\_\_\_\_

Answer: Diaphragm

69) Label E: \_\_\_\_\_

Answer: Peritoneal cavity

70) Label F: \_\_\_\_\_

Answer: Abdominal cavity

71) Label G: \_\_\_\_\_

Answer: Pelvic cavity

72) Label H: \_\_\_\_\_

Answer: Abdominopelvic cavity

73) Label I: \_\_\_\_\_

Answer: Heart

74) Label J: \_\_\_\_\_

Answer: Visceral pericardium

75) Label K: \_\_\_\_\_

Answer: Pericardial cavity

76) Label L: \_\_\_\_\_

Answer: Parietal pericardium

77) Label M: \_\_\_\_\_

Answer: Air space

78) Label N: \_\_\_\_\_

Answer: Balloon